MEET 2008 – Session 5

Below the knee arteries & limb salvage

Present & future of below the knee stenting

M. Bosiers

K. Deloose *P. Peeters*

PRESENT

Clinical perspective – whom to treat…

CRITICAL LIMB ISCHEMIA (CLI)

=

INDICATOR BTK-INTERVENTION

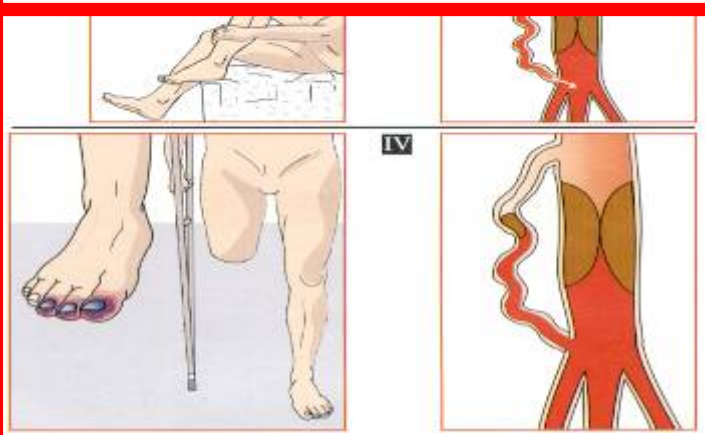

4 Rest pain

5 Non-healing wounds
6 Gangre

Endovascular strategy

≠ Treating angiographic images

= Treating patients' complaints

- Restoring outflow
  - 1 artery straight-line flow to foot

  = PRIMARY GOAL OF ANY TREATMENT

  EXC : Diabetics

  poor collateralisation

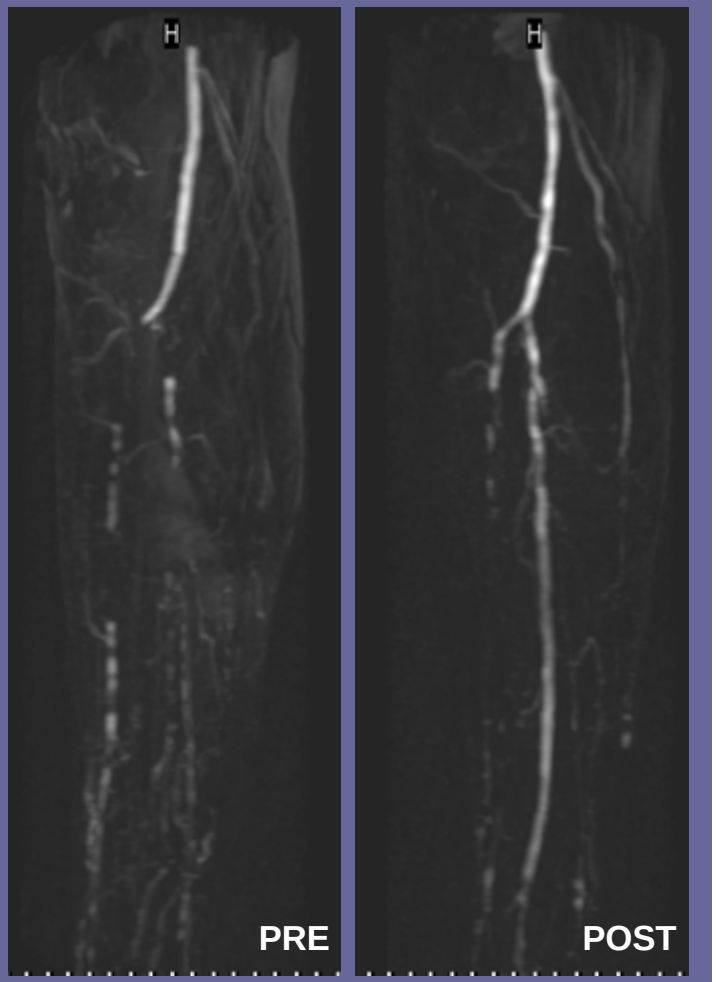

Vessel selection

- Single spot lesions
  - A rare example

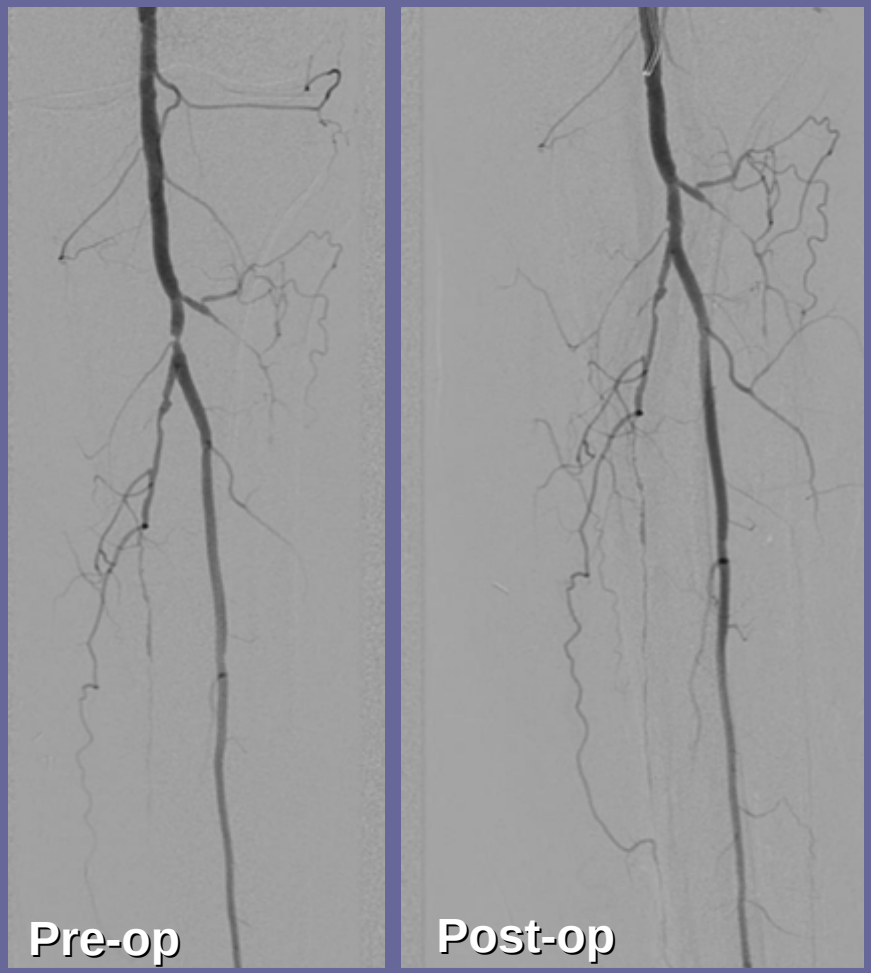

Vessel selection

- Occlusion all 3 BTK vessels
  - Which vessel to treat?

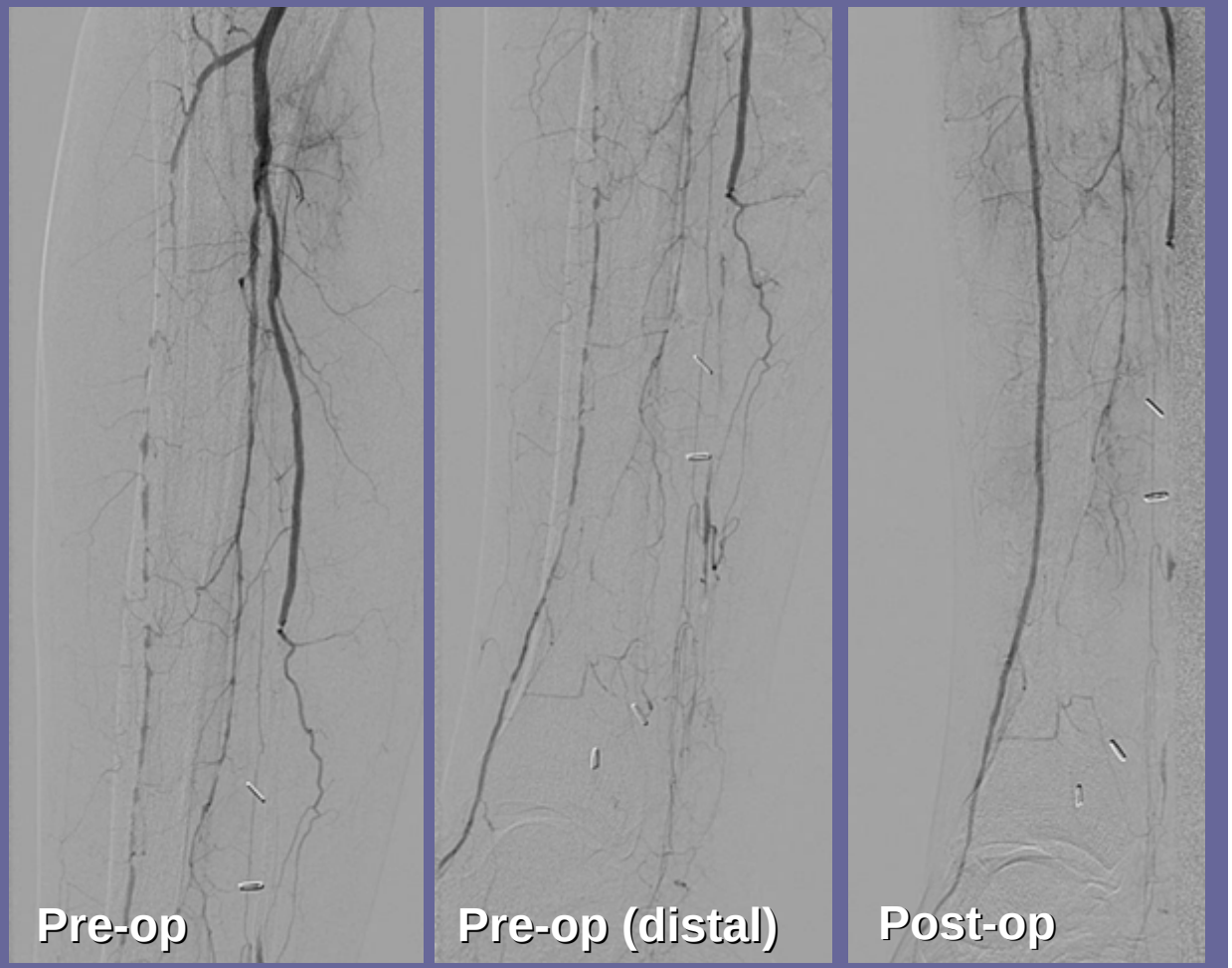

Vessel selection

- Occlusion at distal popliteal: which vessel to treat?

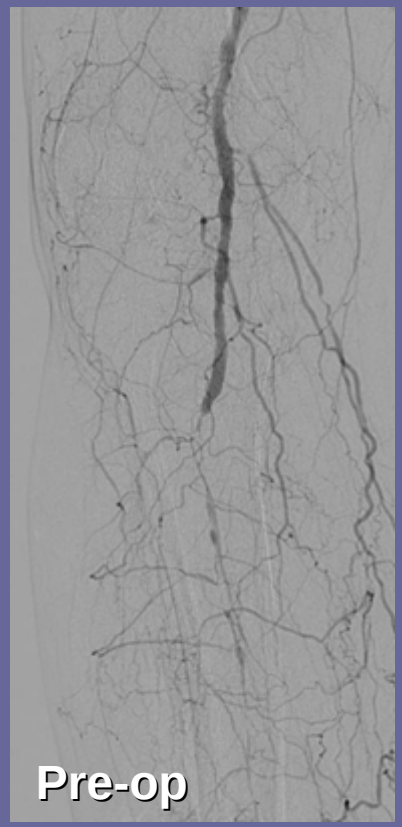

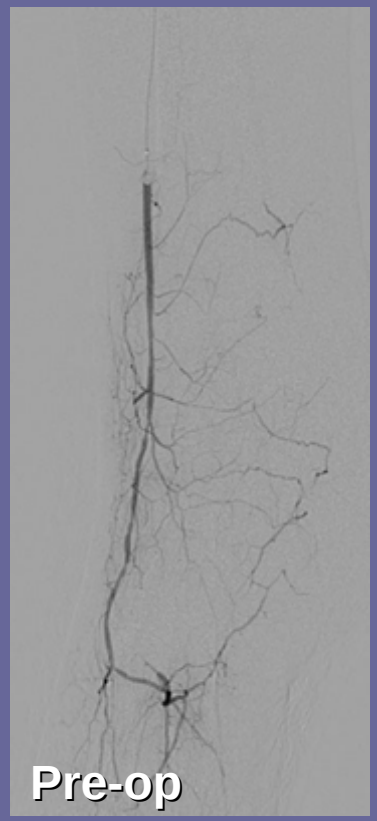

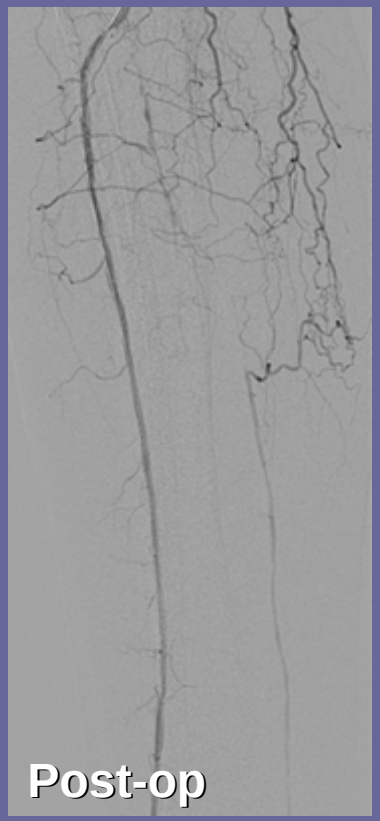

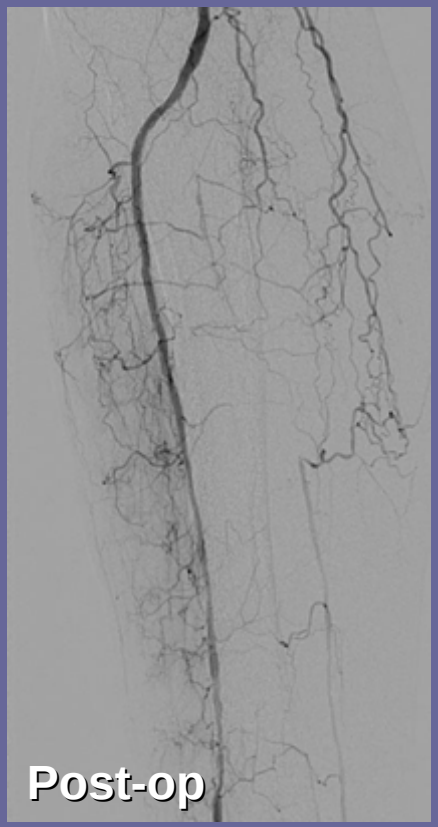

BTK lesions

Device selection

BTK for CLI-patients

Short focal lesion

PTA

Short focal lesion
PTA first

Tandem lesion on Anterior Tibial Artery

Short focal lesion
PTA first

Short occlusion distal ATA

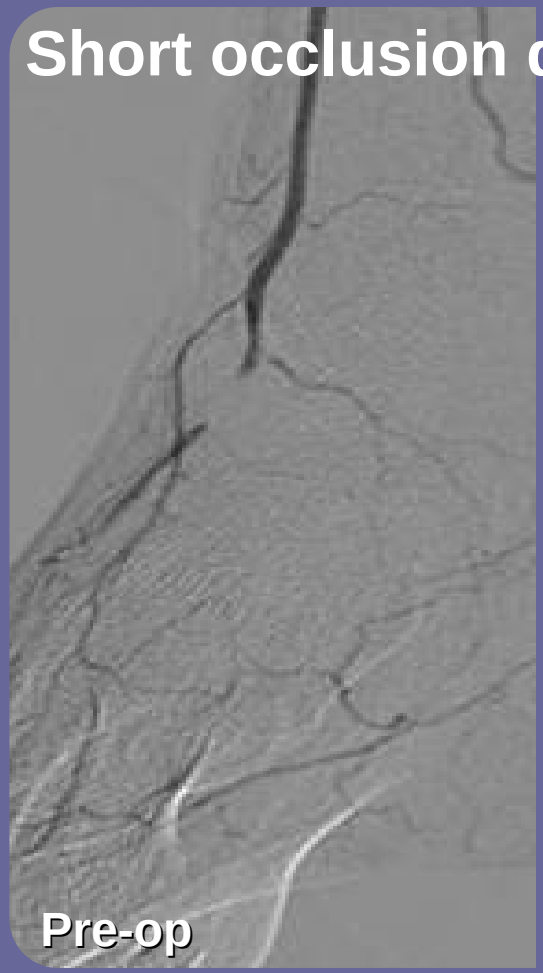

Short focal lesion
PTA first

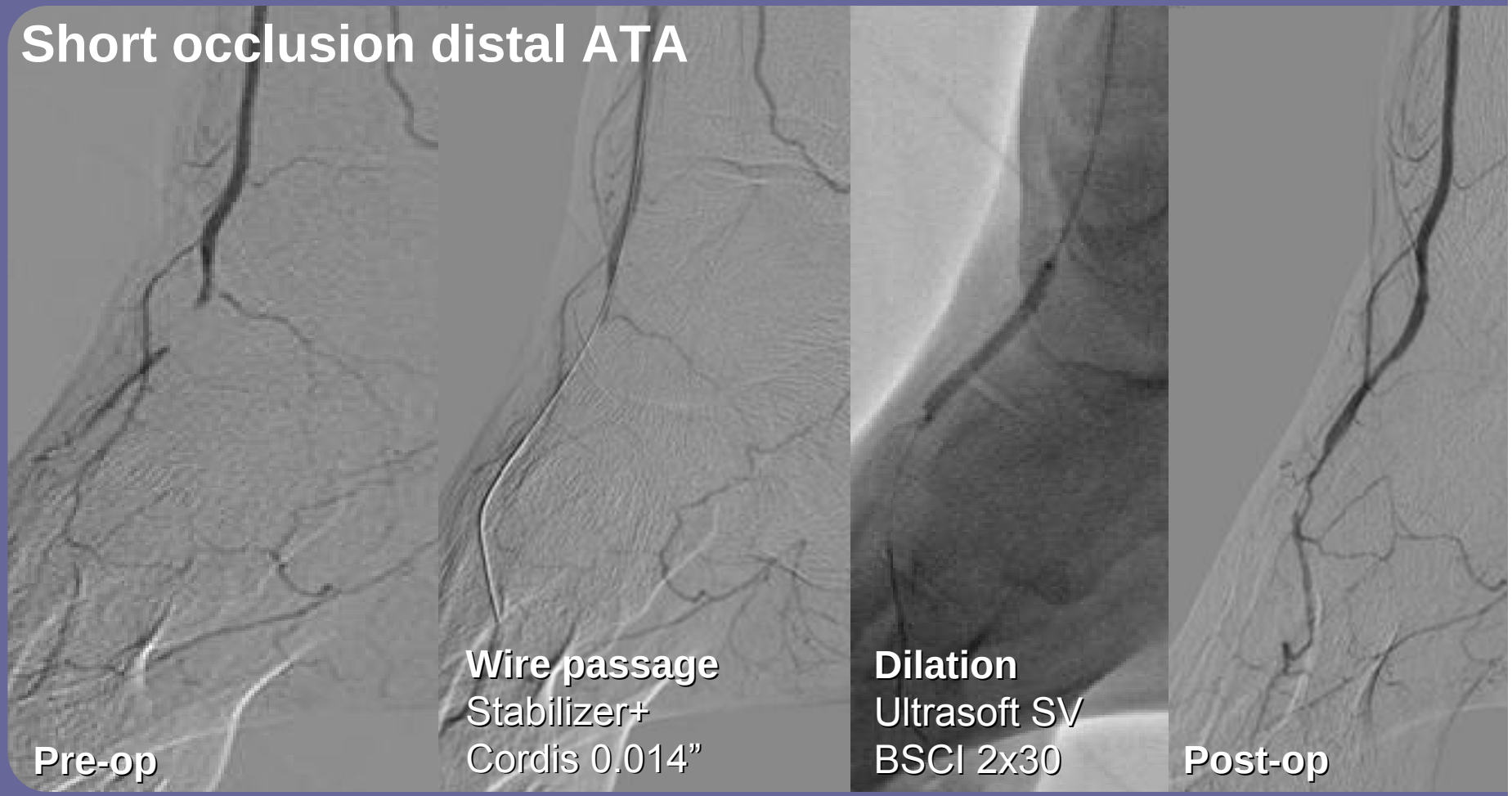

Short focal lesion
PTA first

Short occlusion distal ATA

Short focal lesion
PTA first

Suboptimal PTA outcome

- Flow limiting dissection
- Residual stenosis

➔ BAIL-OUT STENTING

- Balloon-expandable
  - Bare
  - Passive coating
  - Active coating
- Self-expanding
  - Nitinol

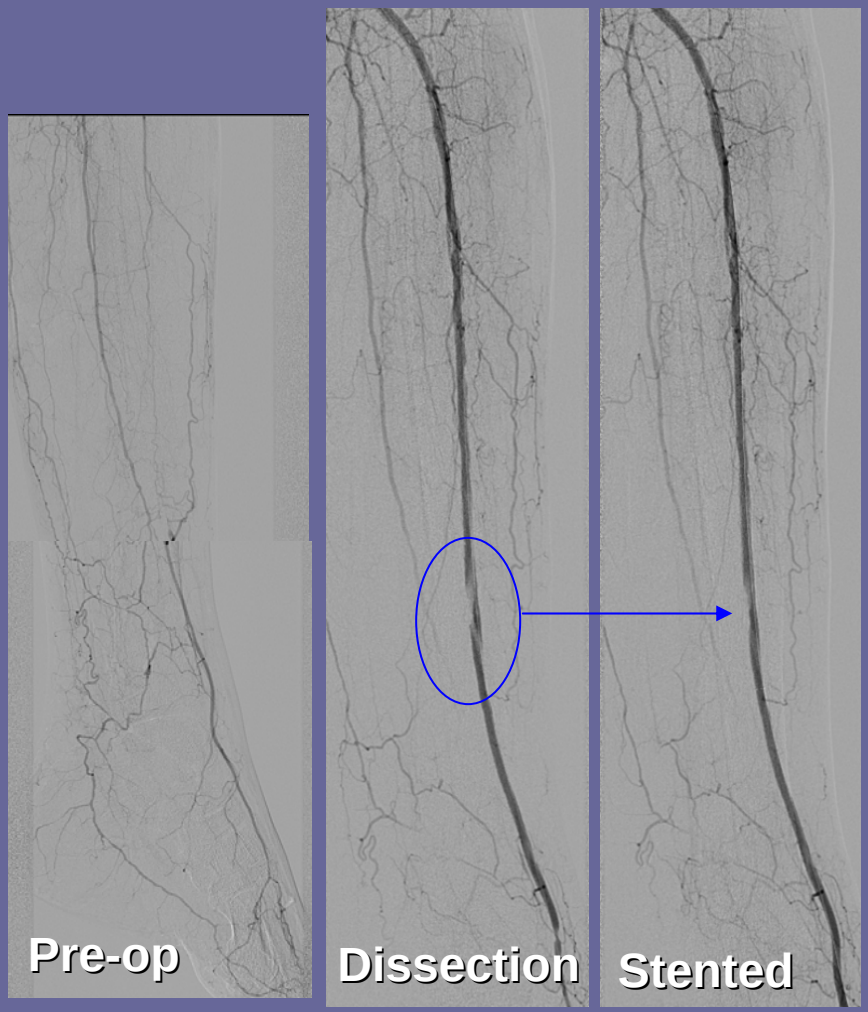

Short focal lesion
PTA first

Suboptimal PTA outcome



BTK lesions

Device selection

BTK for CLI-patients

Short focal lesion

PTA

Calcified/Ostial

Bail-out stenting with **balloon-exp** stent

Short focal lesion

Bail-out stenting : CALCIFIED

Bare metal: Chromis Deep (Invatec)

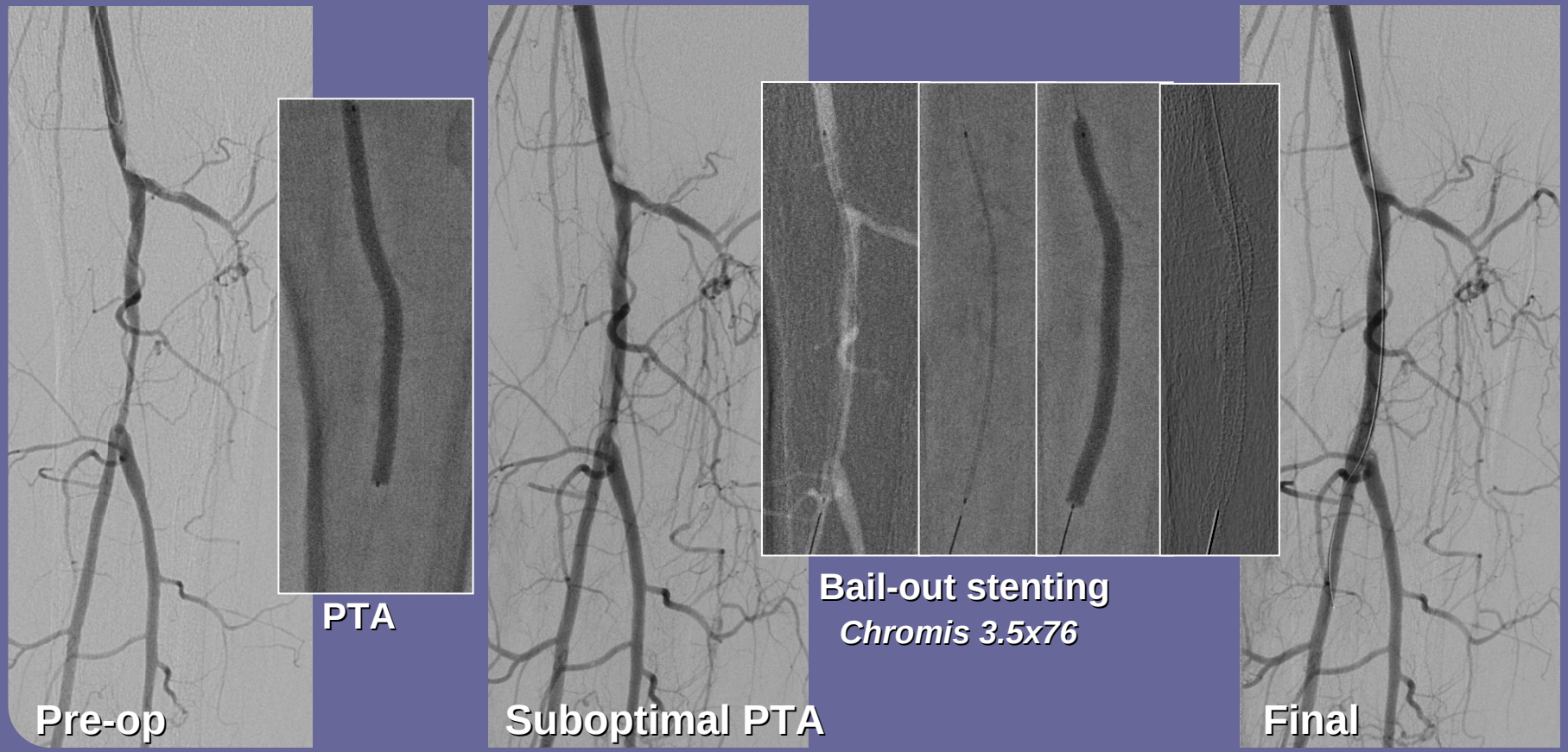

Short focal lesion

Bail-out stenting : OSTIAL

Bare metal: Multilink Vision (Abbott)

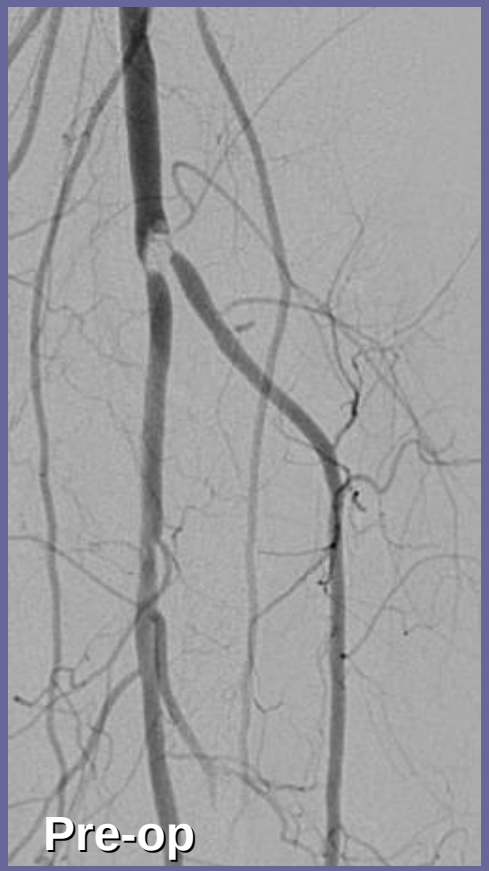

Short focal lesion
Balloon-expandable stents

Bare metal: Multilink Vision (Abbott)

- **Own experience: 12M duplex**
  - Feb - Oct 2005
  - 50 CLI patients
    - Rutherford 4 68%
    - Rutherford 5 32%
  - 62 BTK-lesions
  - 68 Vision stents
- Endpoint
  - 12-month duplex patency

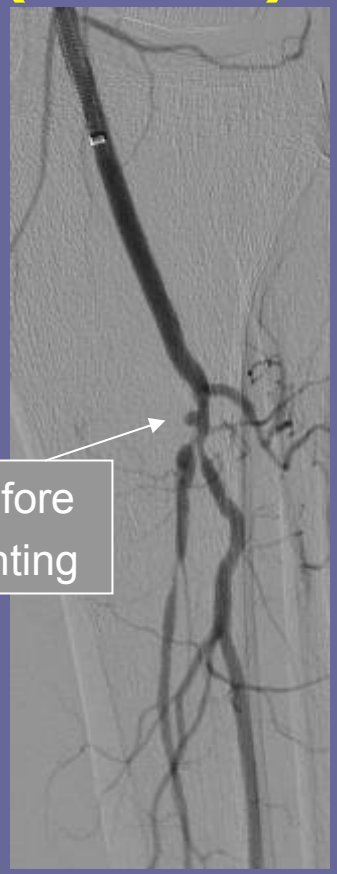

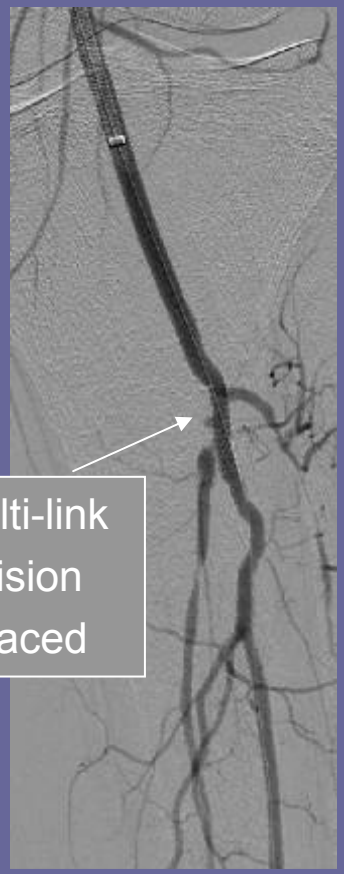

Short focal lesion
Balloon-expandable stents

Bare metal: Multilink Vision (Abbott)

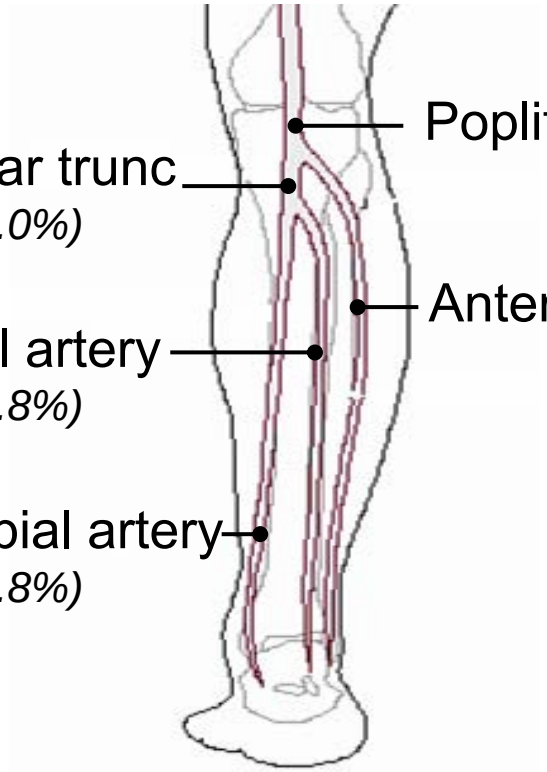

Pre-op stenosis (%)	92.7
Lesion length (mm)	**21.1**
Reference Ø (mm)	3.1

Short focal lesion
Balloon-expandable stents

Bare metal: Multilink Vision (Abbott)

1-year clinical outcome

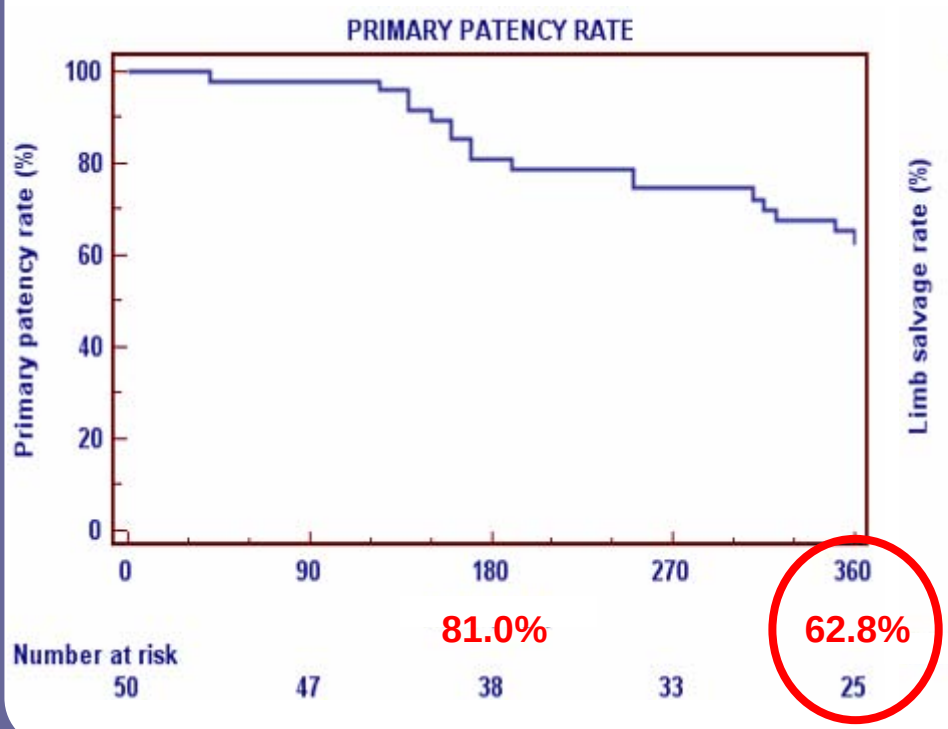

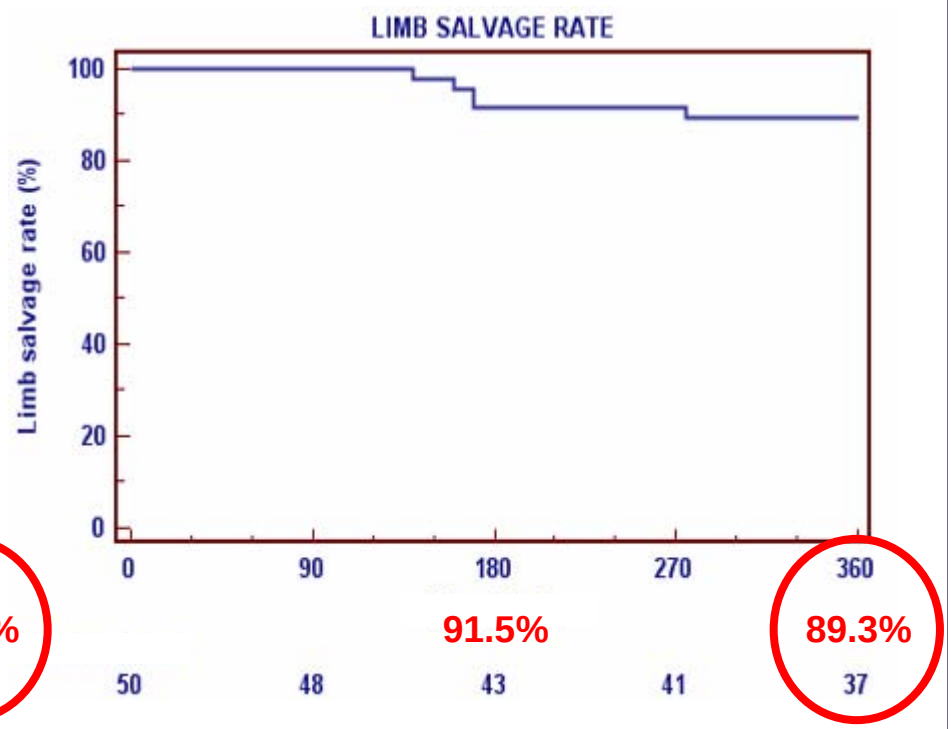

Short focal lesion
Balloon-expandable stents

Dedicated CoCr stent: Chromis Deep (Invatec)

- Primary stenting
  - Chromis In combination with Amphirion Deep Balloon
- March-November 2007
  - **50 CLI patients** (Rutherford 4-5) – 58 stents

Reference diameter	3.1mm
Lesion length	**52.2mm**
Diameter stenosis	90.6%
N° of occlusions	10

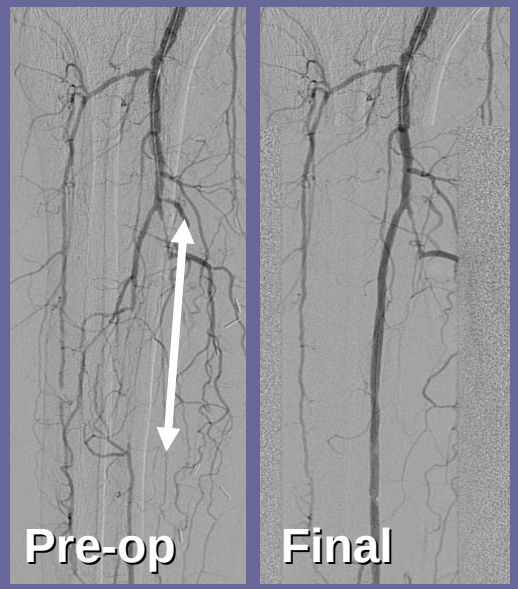

- Primary endpoint: **6-months duplex-based patency**
- Secondary endpoint: 6-months limb salvage & survival rate

Short focal lesion
Balloon-expandable stents

Dedicated CoCr stent: Chromis Deep (Invatec)

6-MONTHS OUTCOME

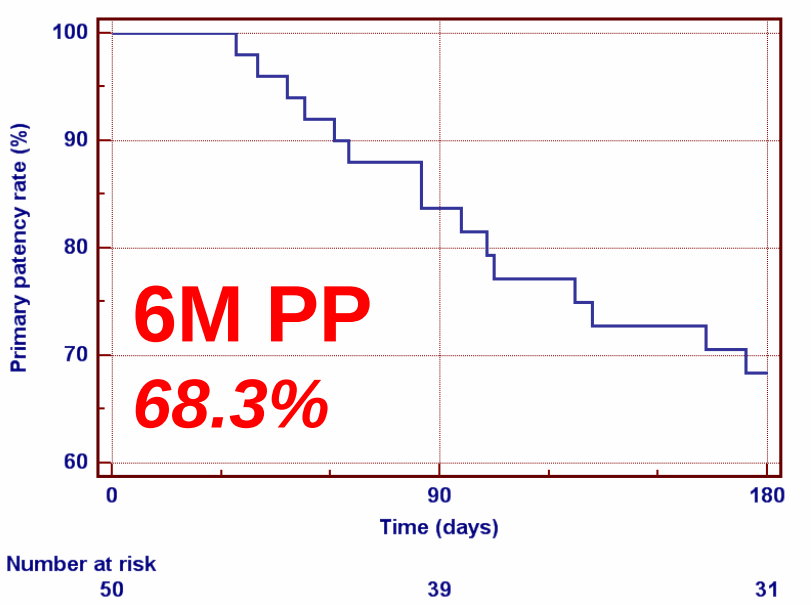

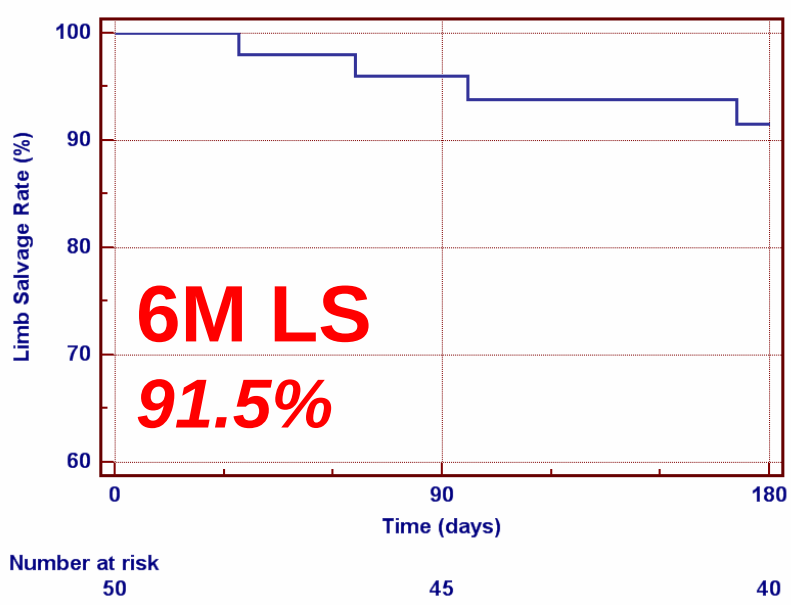

Short focal lesion
Balloon-expandable stents

- Precise placement
  - Ostial lesions
- High radial force
  - Calcified vessels
- Good visibility

BUT THEY MIGHT BREAK

Fracture of a Drug-Eluting Stent in the Tibioperoneal Trunk Following Bifurcation Stenting

J ENDOVASC THER
2007;14:106–109

Alexandra Schwarzmaier-D'Assie, MD[1]; Ronald Karnik, MD[1]; Gerhard Bonner, MD[1]; Joachim Vavrik, MD[2]; and Joerg Slany, MD[1]

Departments of [1]Medicine II and [2]Radiology, KA Rudolfstiftung, Vienna, Austria.

BTK lesions

Device selection

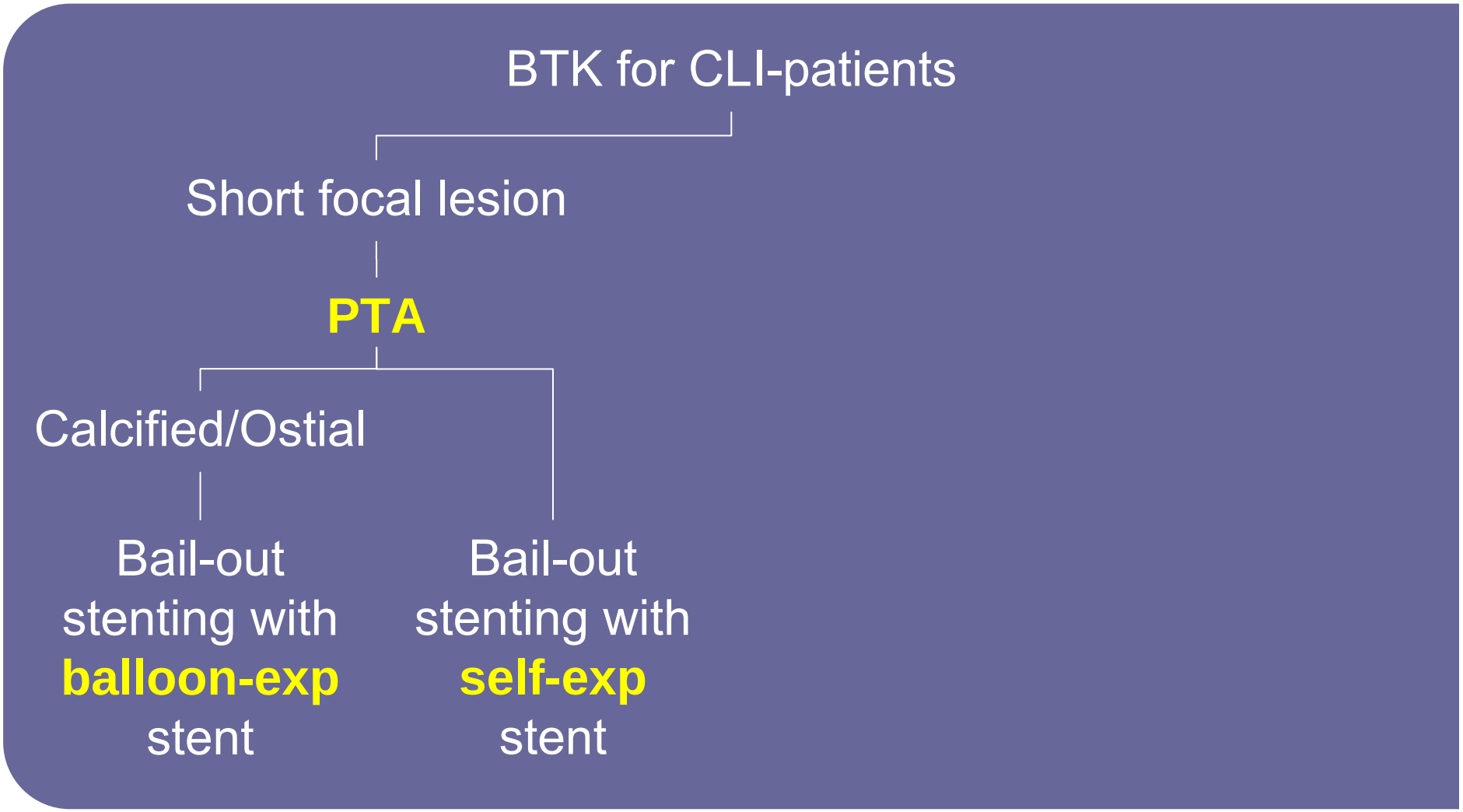

Short focal lesion
Self-expanding stents

Nitinol: Xpert (Abbott)
Maris Deep (Invatec)
Astron Pulsar (Biotronik)

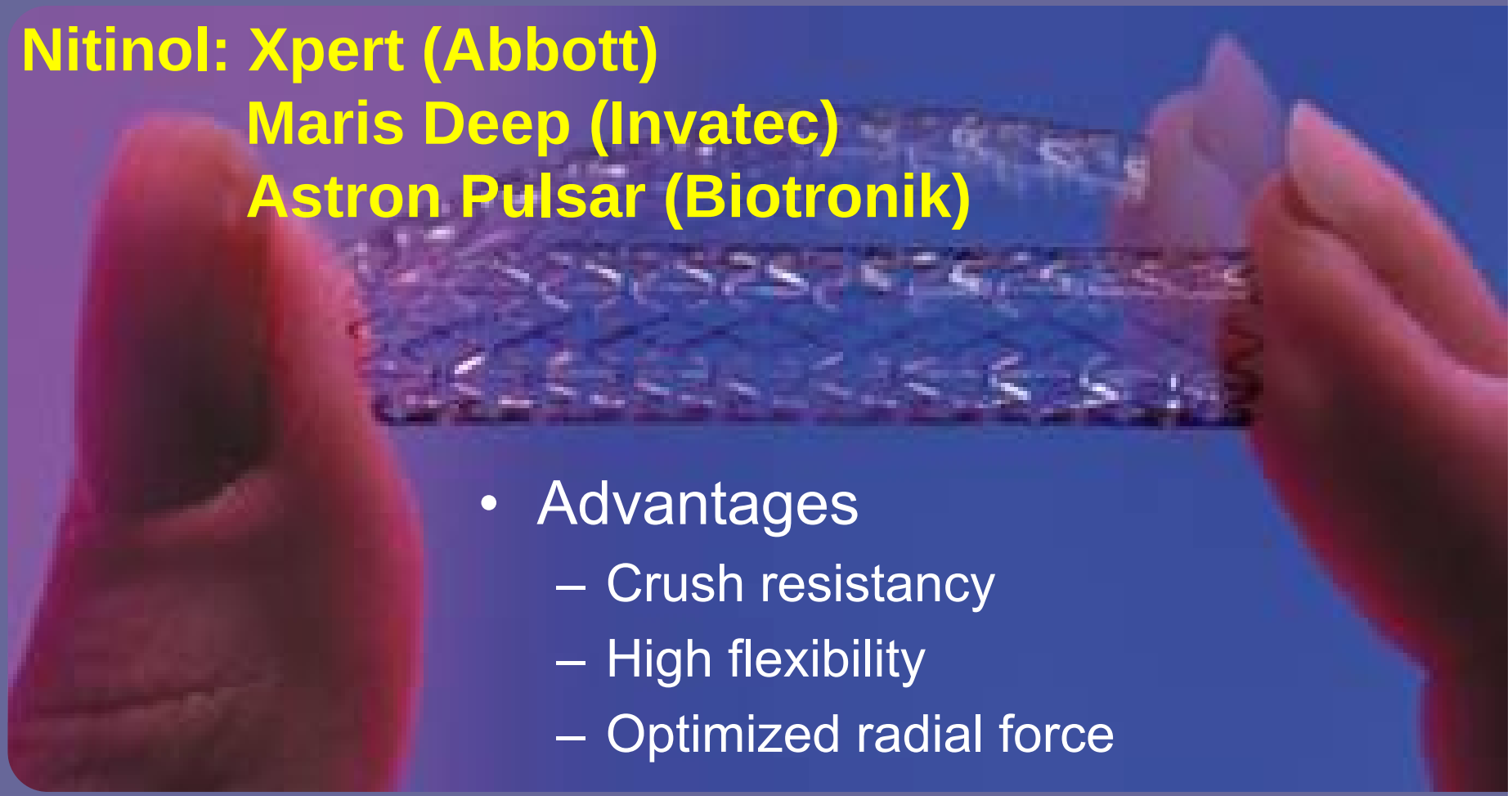

- Advantages
  - Crush resistancy
  - High flexibility
  - Optimized radial force

Short focal lesion
Self-expanding stents

Nitinol: Xpert (Abbott)

- Dedicated design for small vessels
  - Do **not** place a large vessel stent in smaller diameters!
    - Metal overload + Impaired flow dynamics

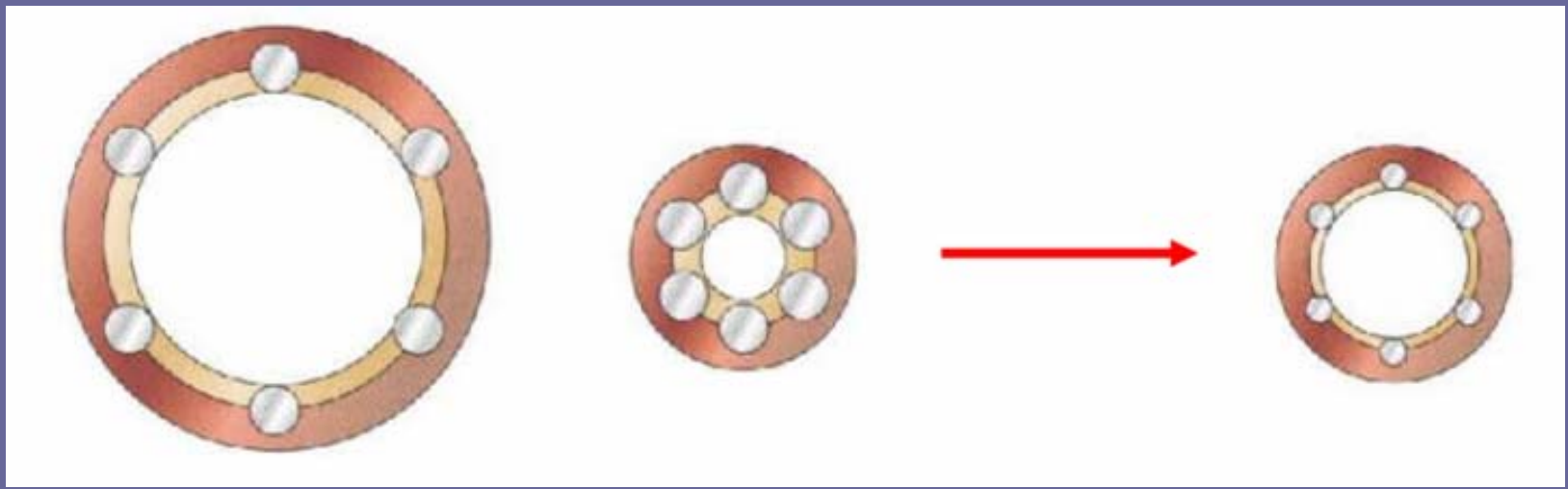

Short focal lesion
Self-expanding stents

Nitinol: Xpert (Abbott)

- **Own experience**
  - May 2005 – Dec 2005
  - Infrapopliteal lesions
    - 47 CLI patients (Ruth 4-5)
    - **51 limbs** - 58 lesions - 67 stents
    - Mean lesion length = **32.4 mm**
    - **53.4%** occlusions

Primary endpoint:
1-year **angiographic** patency
- Absence of >50% stenosis on QVA

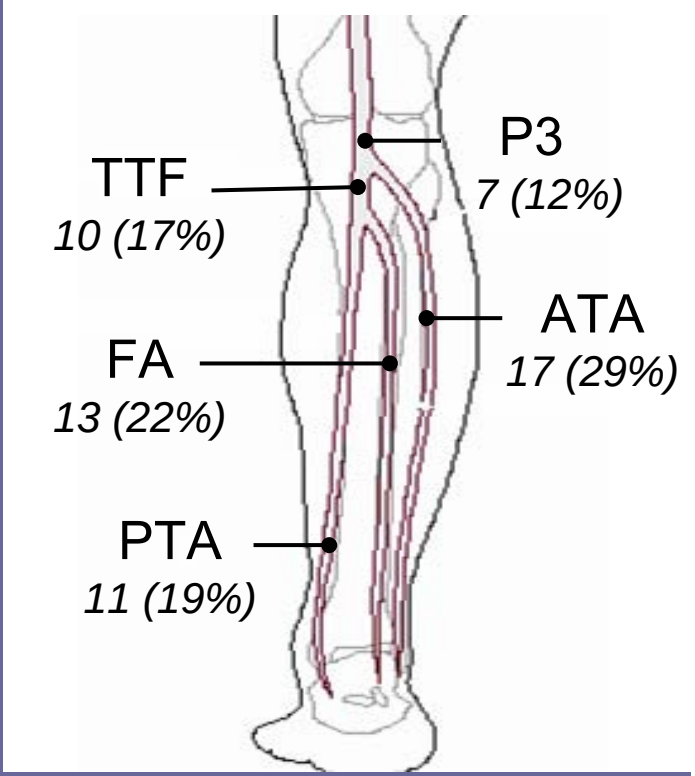

Bosiers et al. J Cardvasc Surg 2007 Aug;48(4):455-61.

Short focal lesion
Self-expanding stents

Nitinol: Xpert (Abbott)

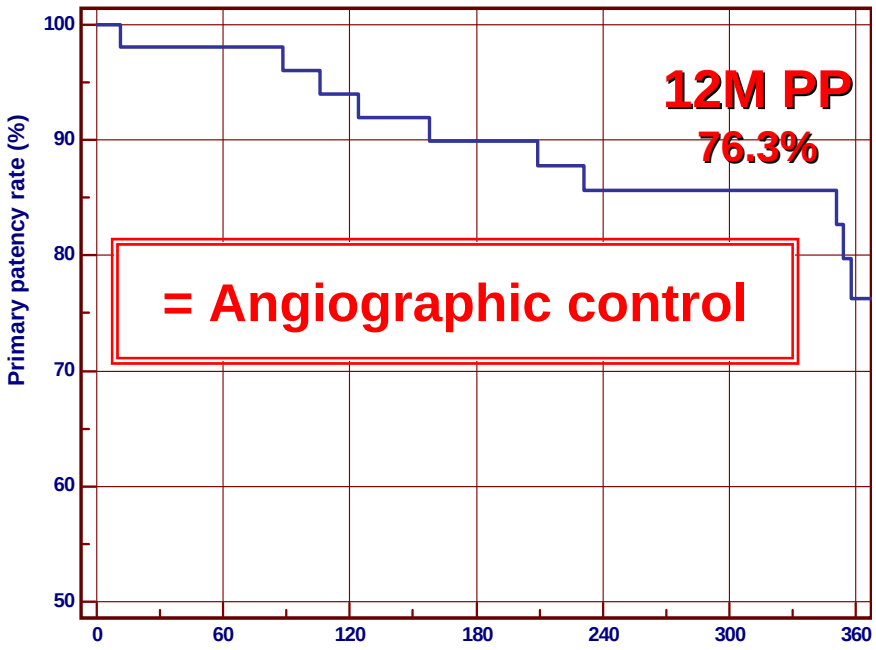

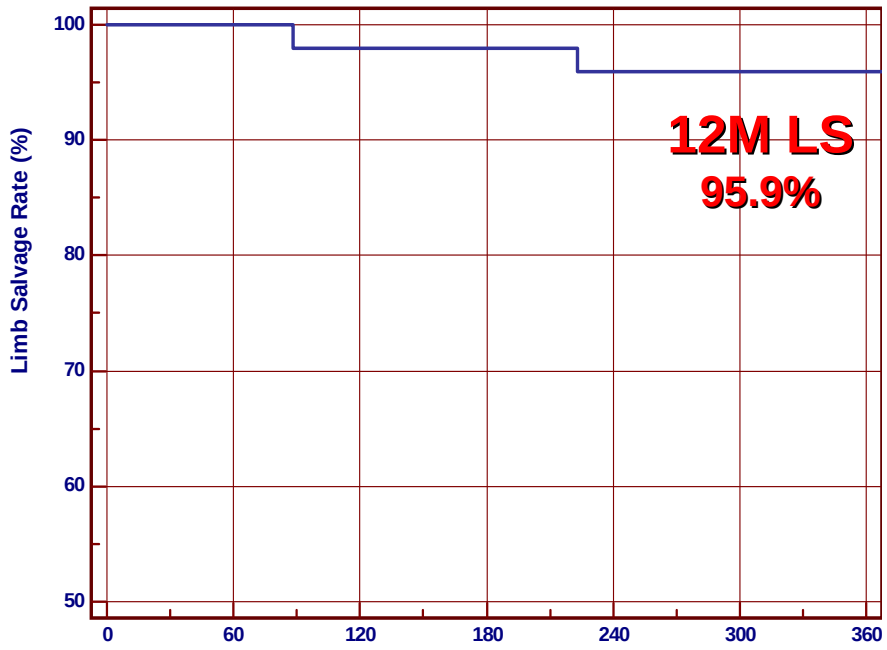

Bosiers et al. J Cardvasc Surg 2007 Aug;48(4):455-61.

Short focal lesion
Self-expanding stents

Nitinol: Xpert (Abbott)

- **Own experience (extension)**
  - May 2005 – Nov 2007
  - Infrapopliteal lesions
    - 94 CLI patients (Ruth 4-5)
    - **102 limbs** - 111 lesions - 134 stents
    - Mean lesion length = **33.2 mm**
    - **33.4%** occlusions

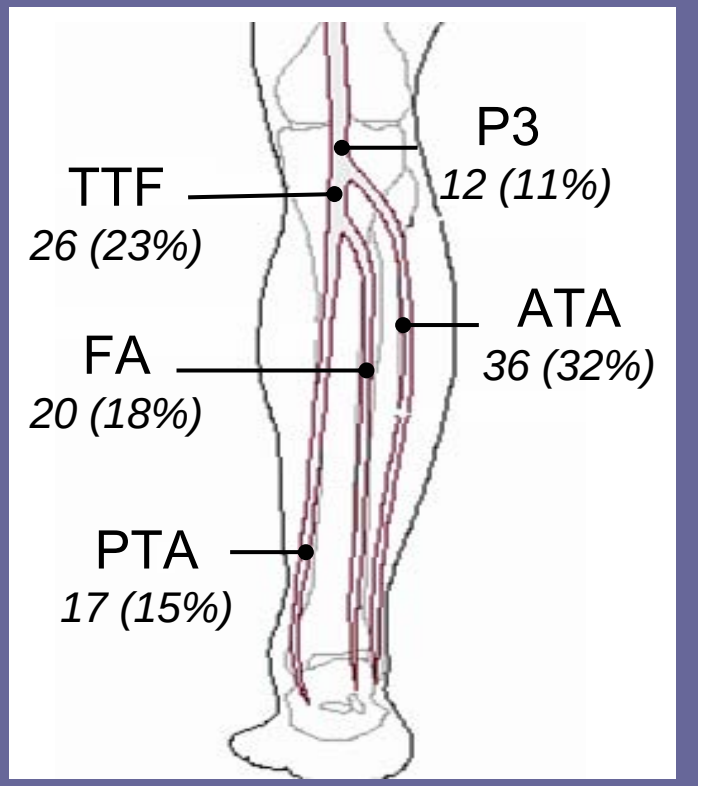

Endpoints

2-year **duplex-derived** patency & limb salvage

Short focal lesion
Self-expanding stents

Nitinol: Xpert (Abbott)

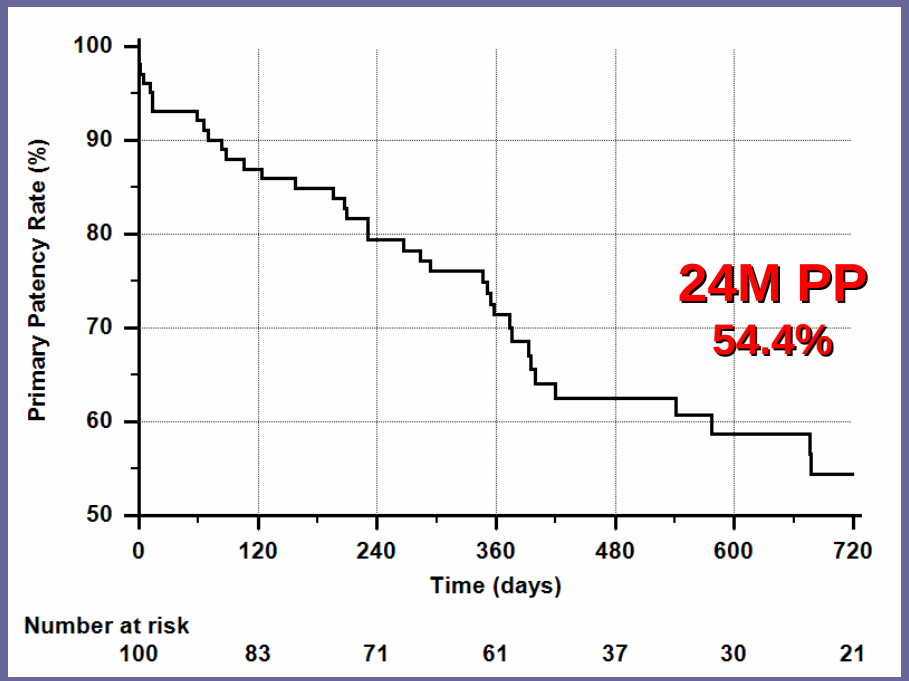

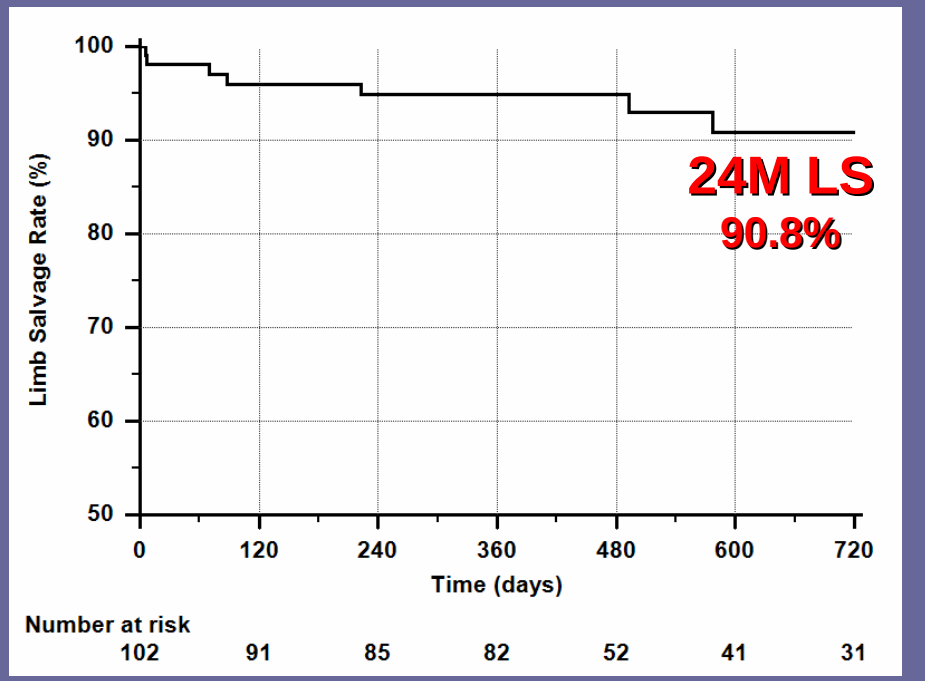

Bosiers et al. Vascular 2008 – submitted.

BTK lesions

Device selection

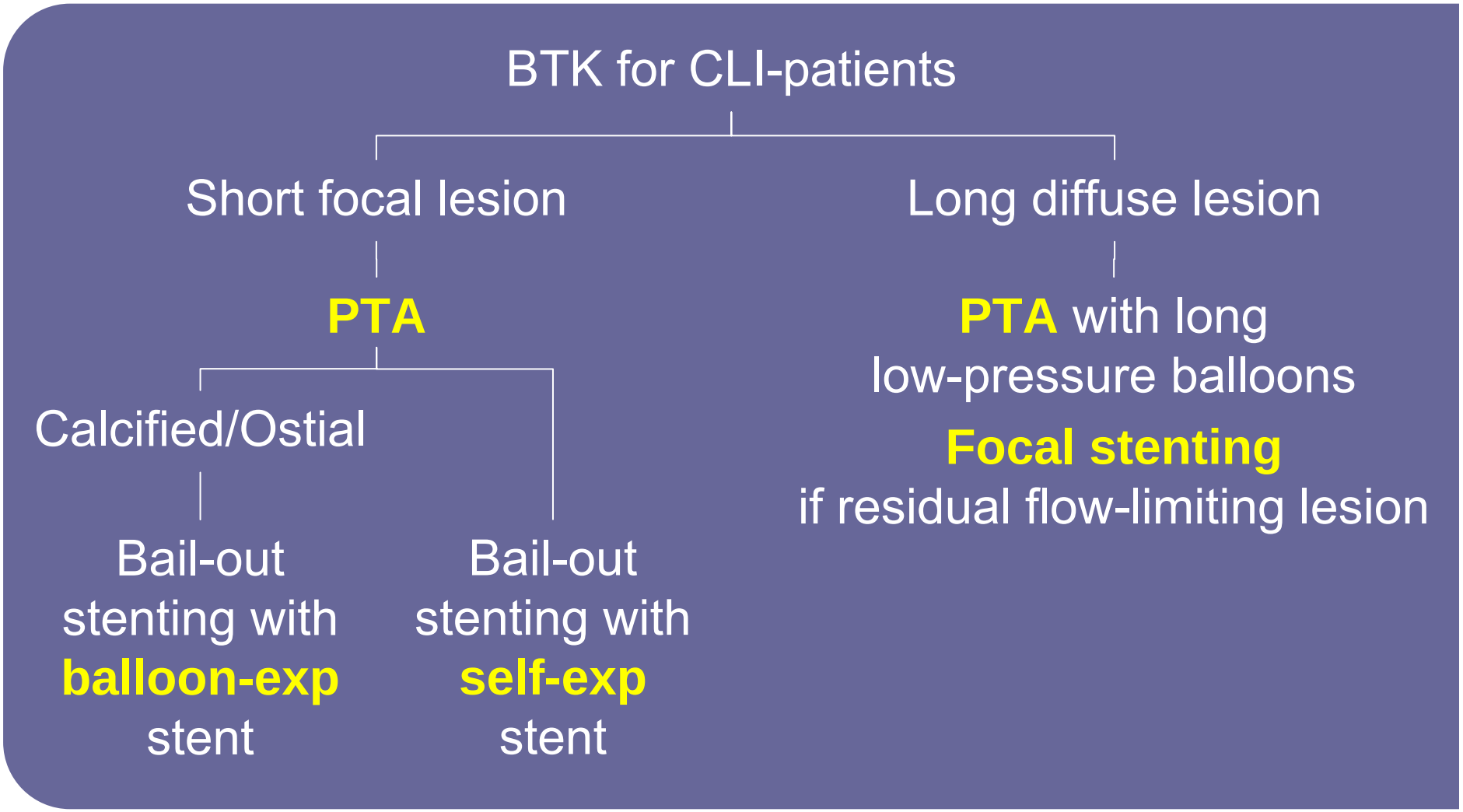

Long diffuse lesion
PTA first

Long diffused lesion of Posterior Tibial Artery

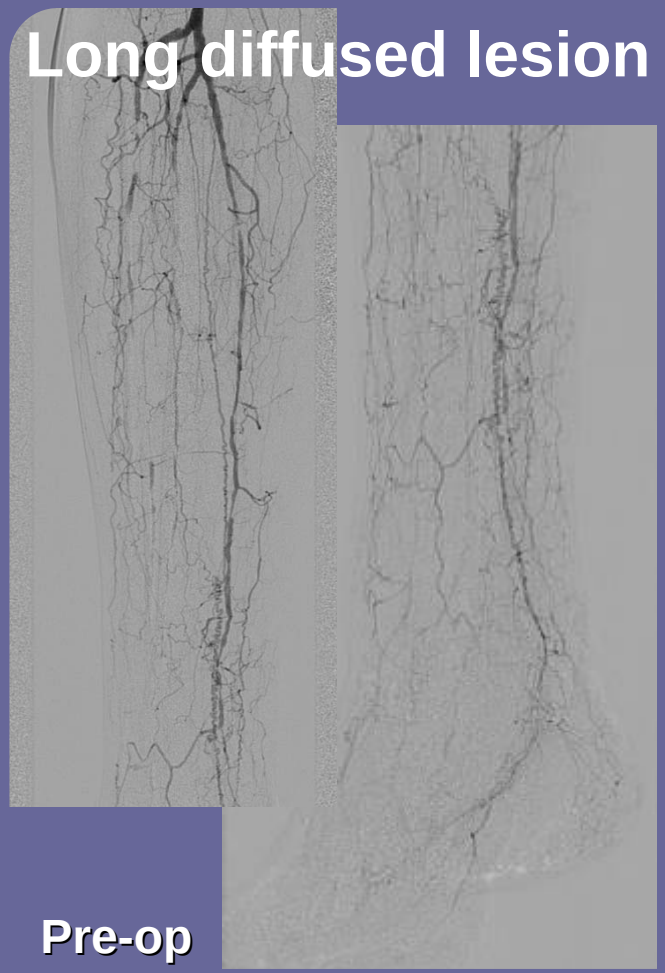

Pre-op

Baseline wound status

Long diffuse lesion
PTA first

Long diffused lesion of Posterior Tibial Artery

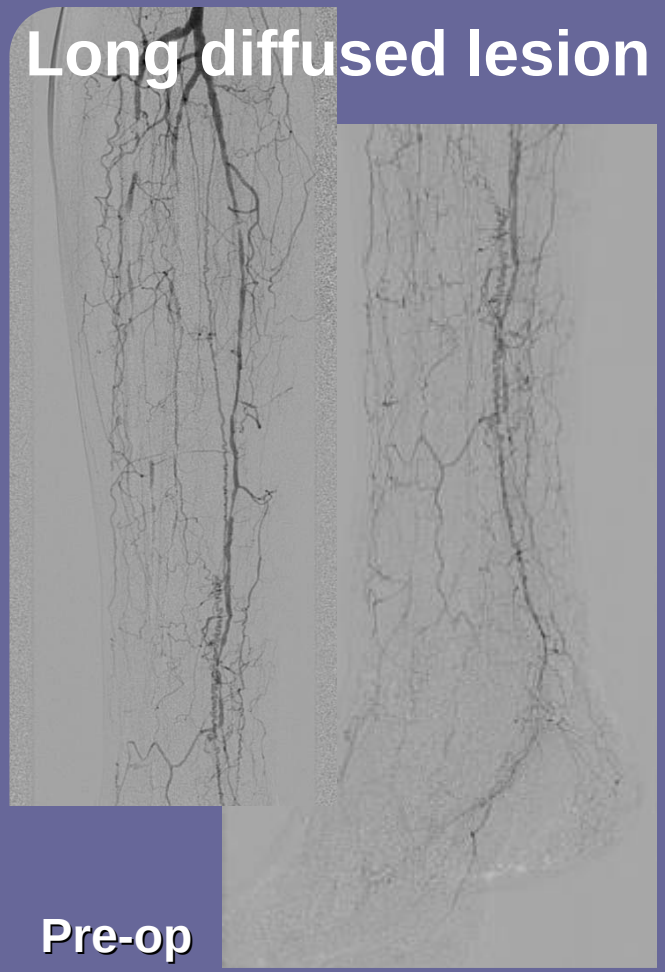

Pre-op

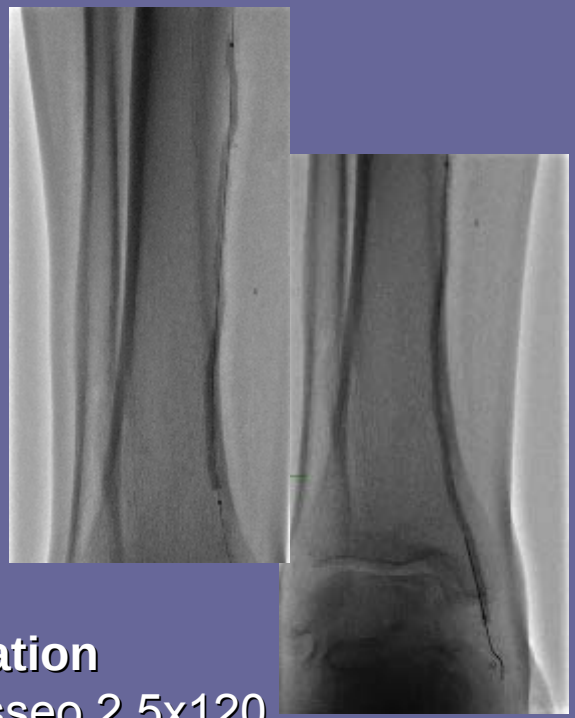

Dilation
Passeo 2.5x120

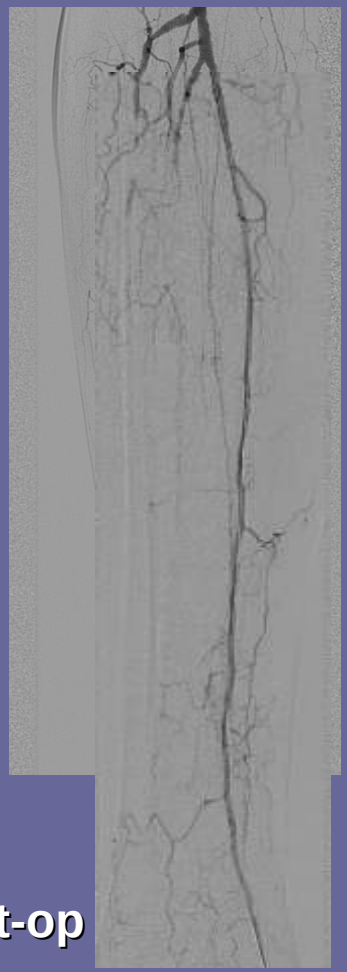

Post-op

Long diffuse lesion
PTA first

Dedicated wound care

Wound evolution

3-months post- intervention

6-months post- intervention

Long diffuse lesion
PTA first

Distal lesion on Posterior Tibial Artery

Pre-op

Wound status at baseline

Long diffuse lesion
PTA first

Distal lesion on Posterior Tibial Artery

Pre-op

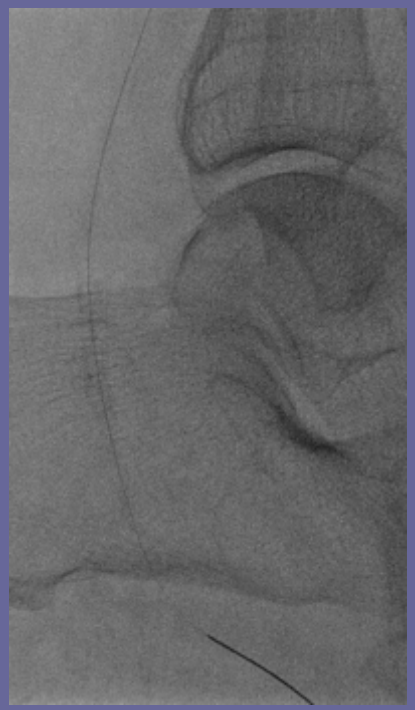

Dilation
Fox SV 2.0x80

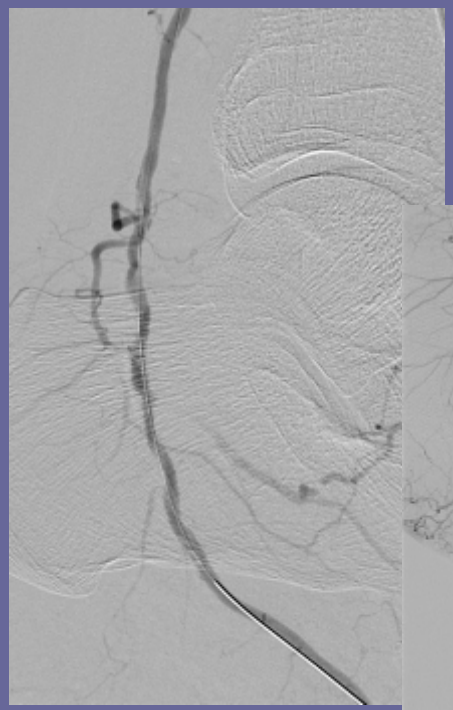

Post-op

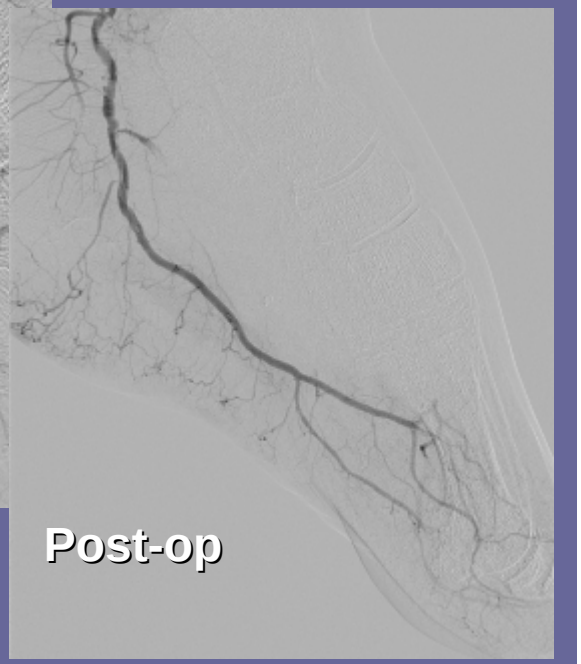

Post-op

Long diffuse lesion
PTA first

Distal lesion on Posterior Tibial Artery

Long diffuse lesion
PTA and bail-out focal stenting

Long occlusion Anterior Tibial Artery

Pre-op

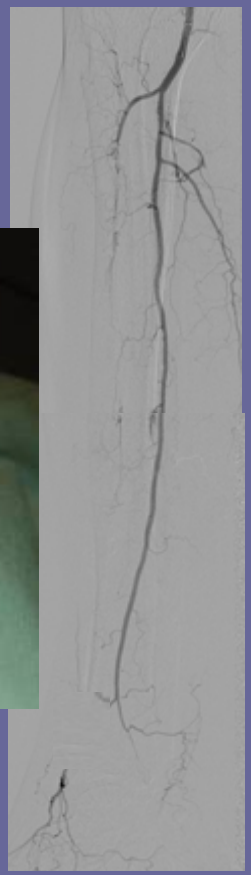

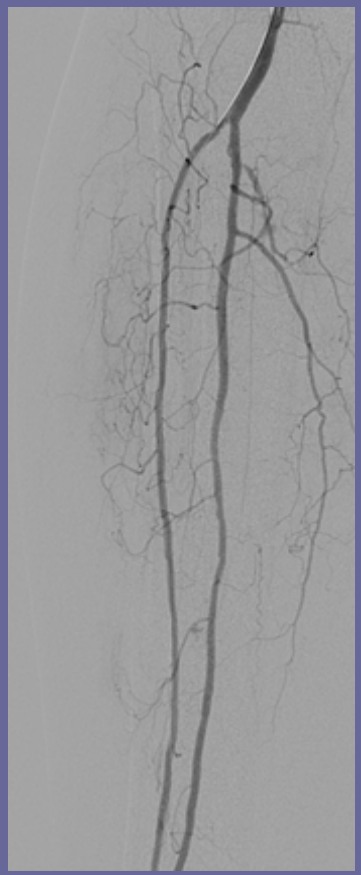

Dilation ATA
Fox SV 2.5x120
(2 times)

→ Resulting in distal flow limiting dissection

Long diffuse lesion
PTA and bail-out focal stenting

Long occlusion Anterior Tibial Artery

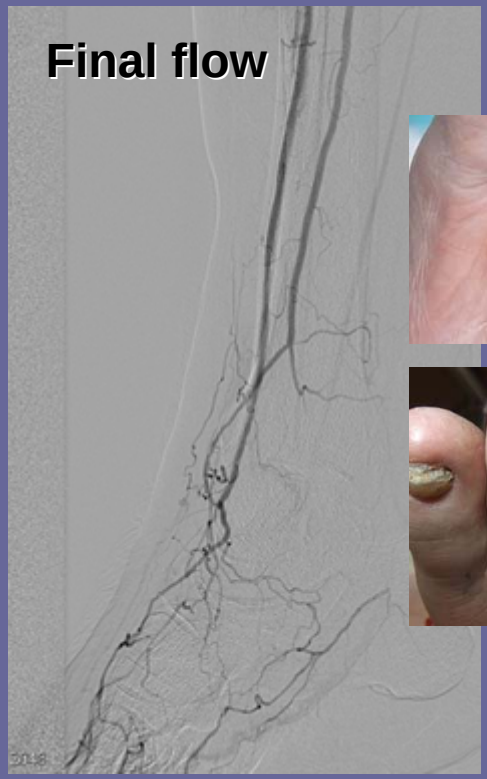

FUTURE

Drug eluting stents?

10.30	SESSION 5	BELOW THE KNEE ARTERIES & LIMB SALVAGE			
10.30	State of the Art	Present & future of below the knee stenting, M. Bosiers			
10.50	Recorded Live Cases	P. Commeau, M. Fusaro, P. Peeters			
11.35	Crossfire Controversy 2	Drug eluting stents will solve the problem!	Pro: K. Katsanos	Against: M. Bosiers	Discussion
11.50	Lessons & Perspectives	Retrograde approach for below the knee angioplasty, M. Fusaro CO2 angiography for peripheral interventional procedures in severe renal insufficiency, E. Calabrese Subintimal angioplasty of tibial arteries for limb salvage, P. Schneider Place of debulking devices for below the knee recanalization, P. Peeters Update on absorbable stents, M. Wholey			

FUTURE

Ongoing multicenter CRTs

Achilles ***(Cordis)***

PTA vs sirolimus eluting stent

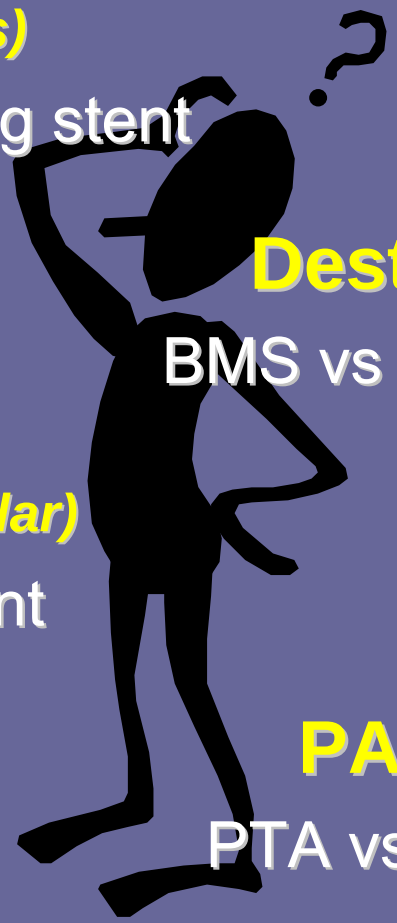

Destiny ***(Abbott Vascular)***

BMS vs everolimus eluting stent

XXS ***(Abbott Vascular)***

PTA vs nitinol stent

PADI ***(Boston Scientific)***

PTA vs paclitaxel eluting stent

Conclusion

Endovascular strategy

- **PTA** is **first** approach
- Stenting after **suboptimal PTA** improves outcomes
  - **Dedicated BTK** stents should be used
- For **short focal lesions**, current single center studies indicate that **primary BTK stenting** can be a viable option, but ongoing randomized controlled trials will give the final answer